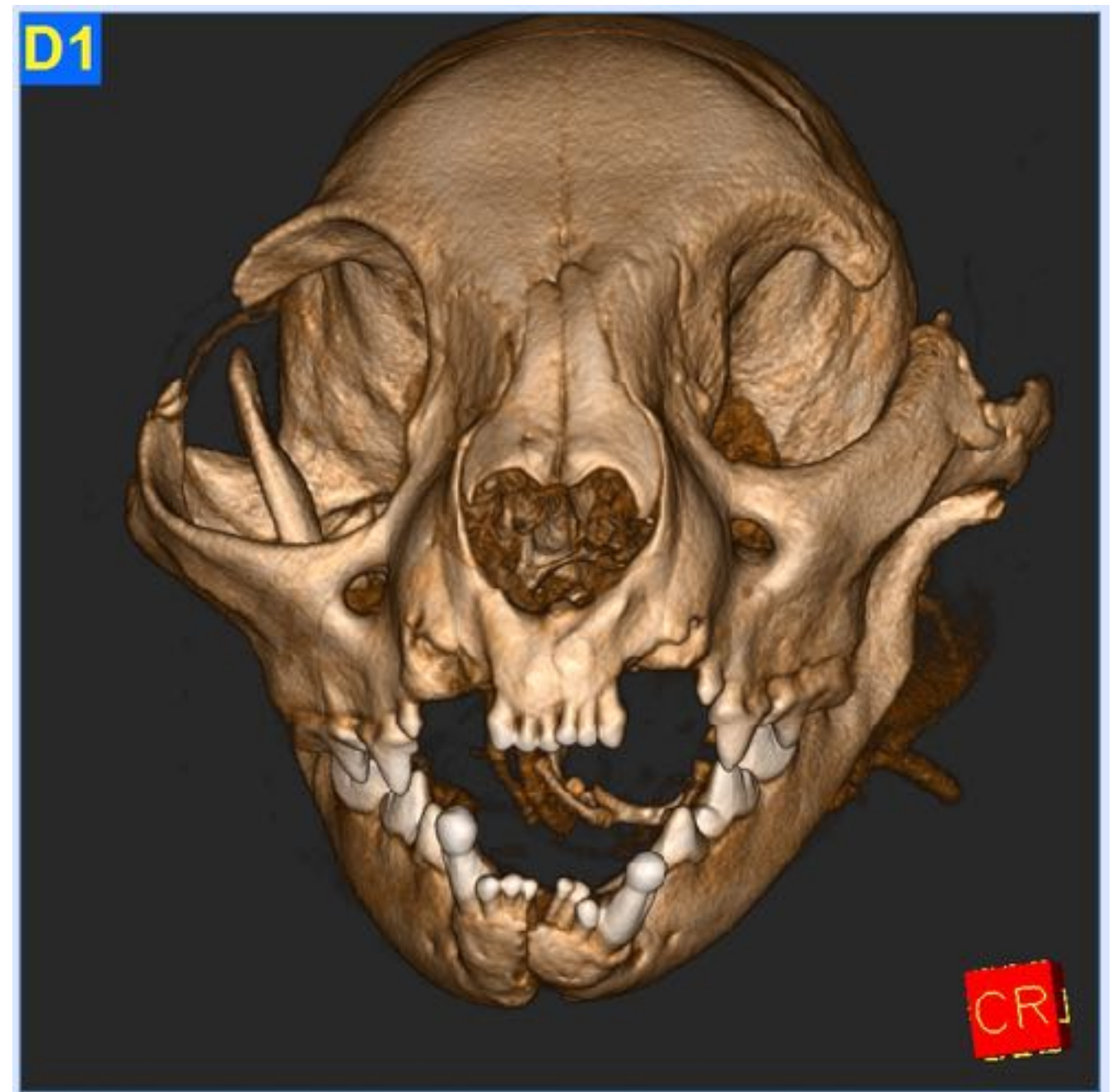
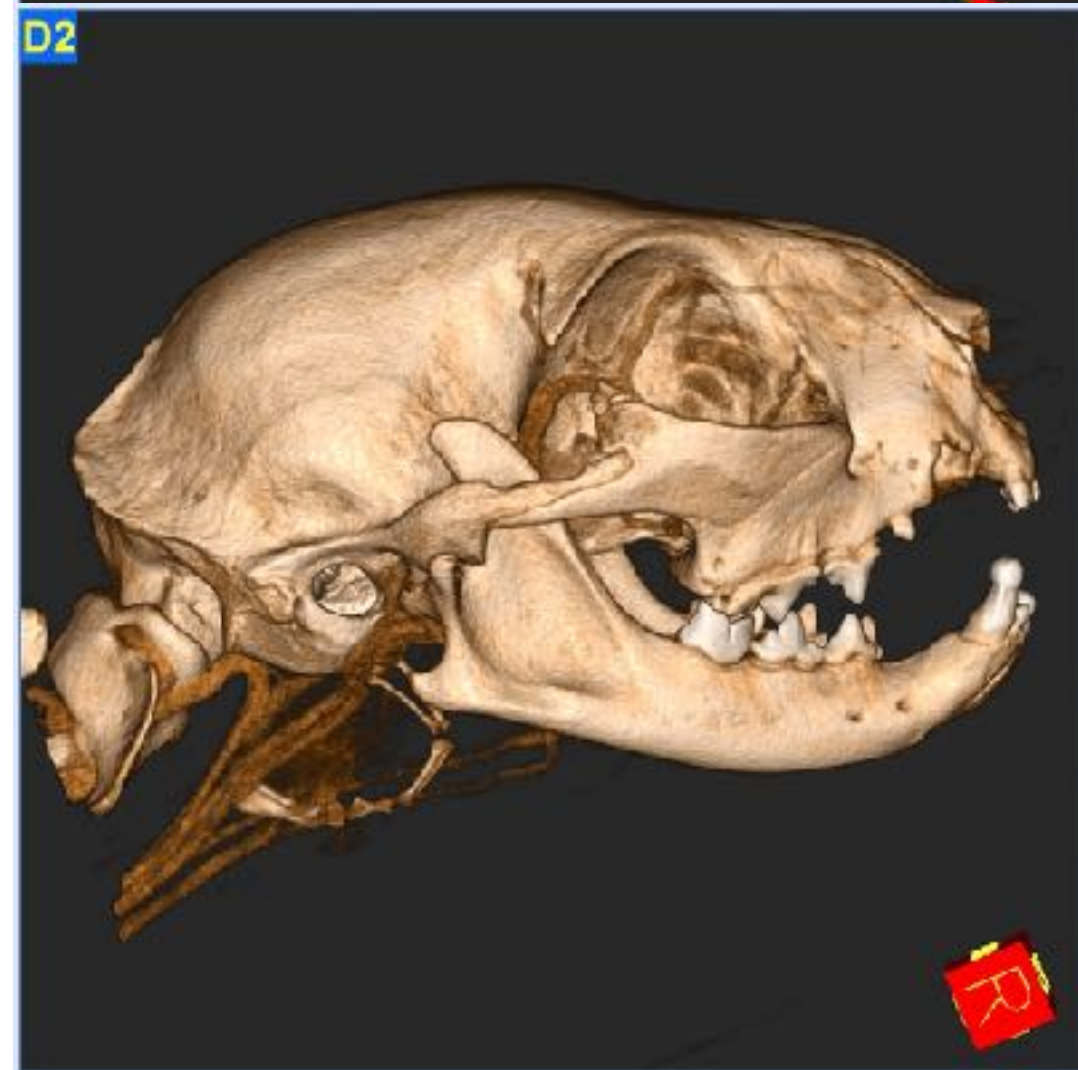
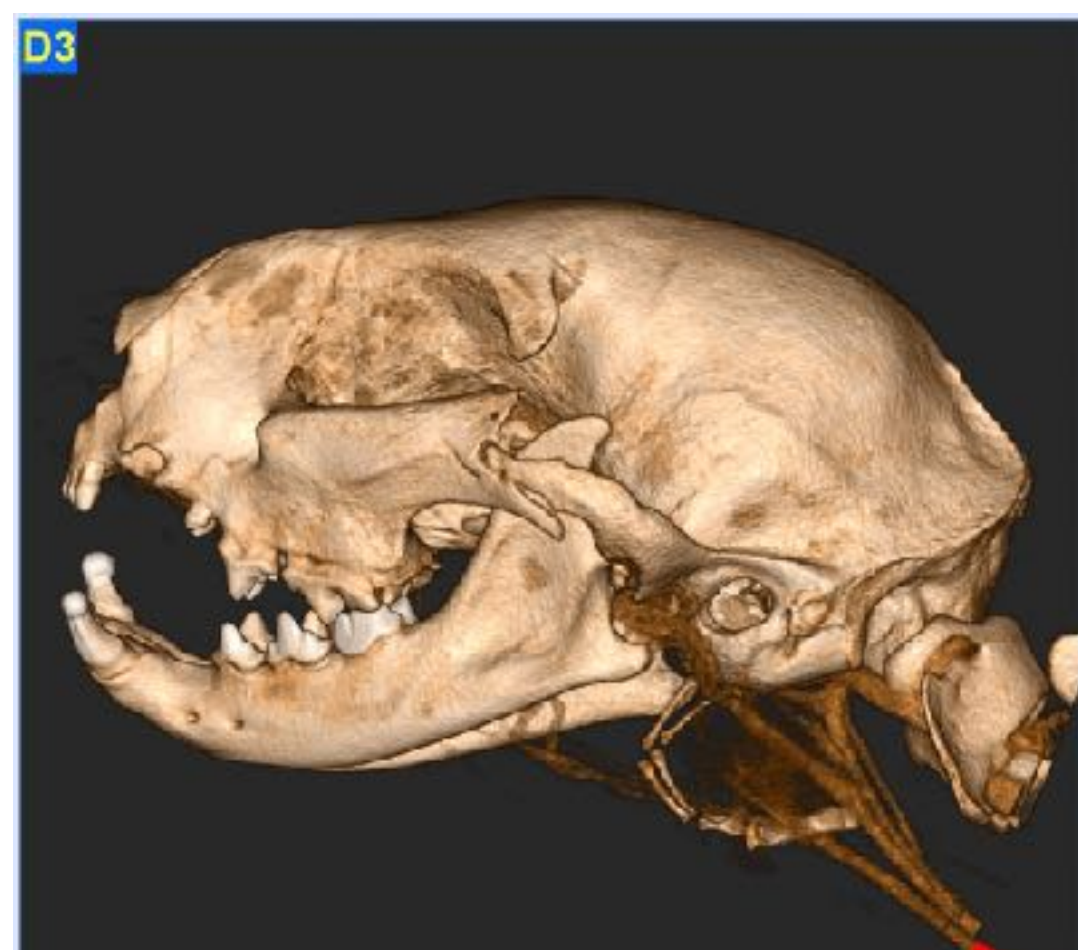
# Melba

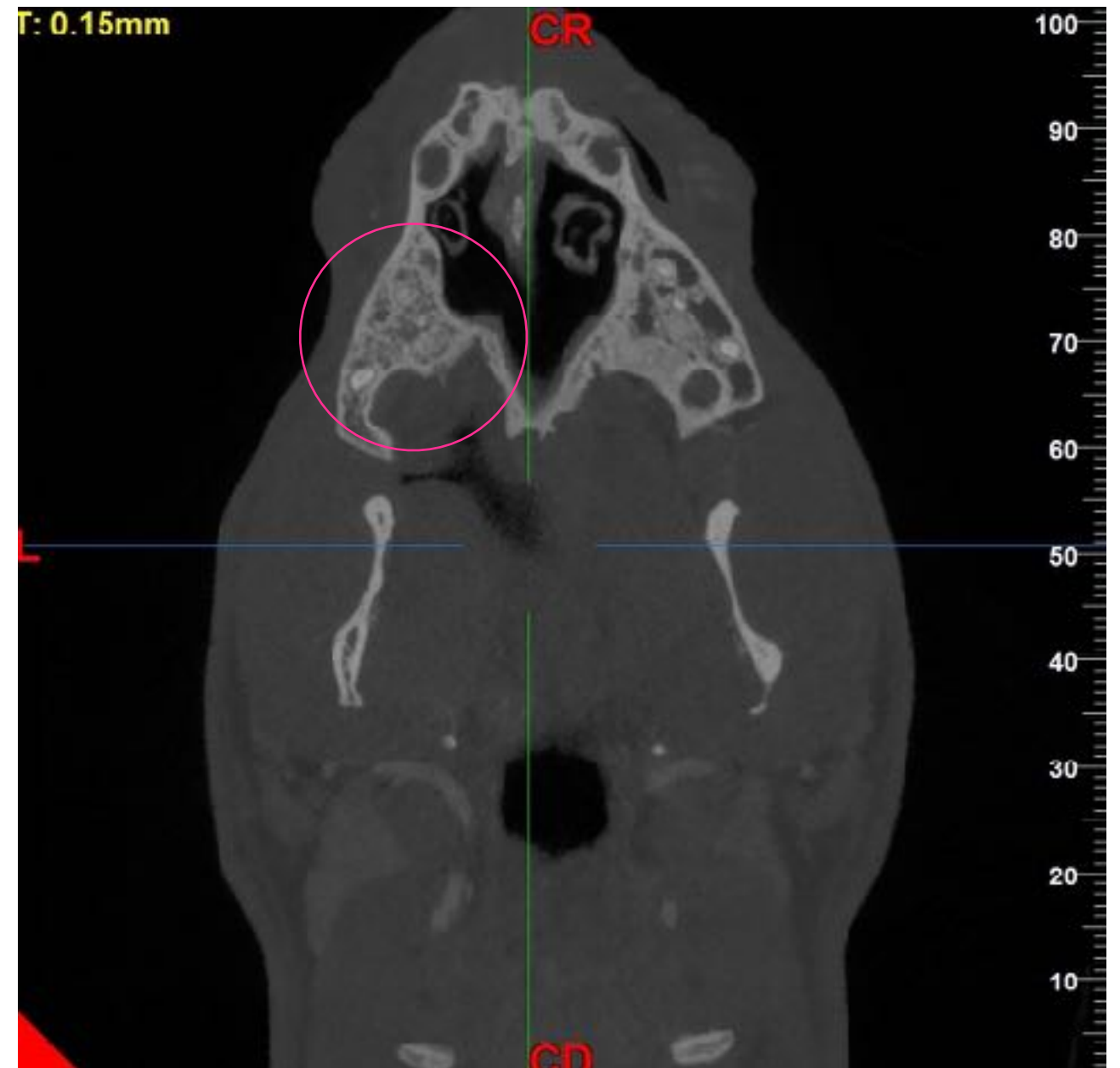
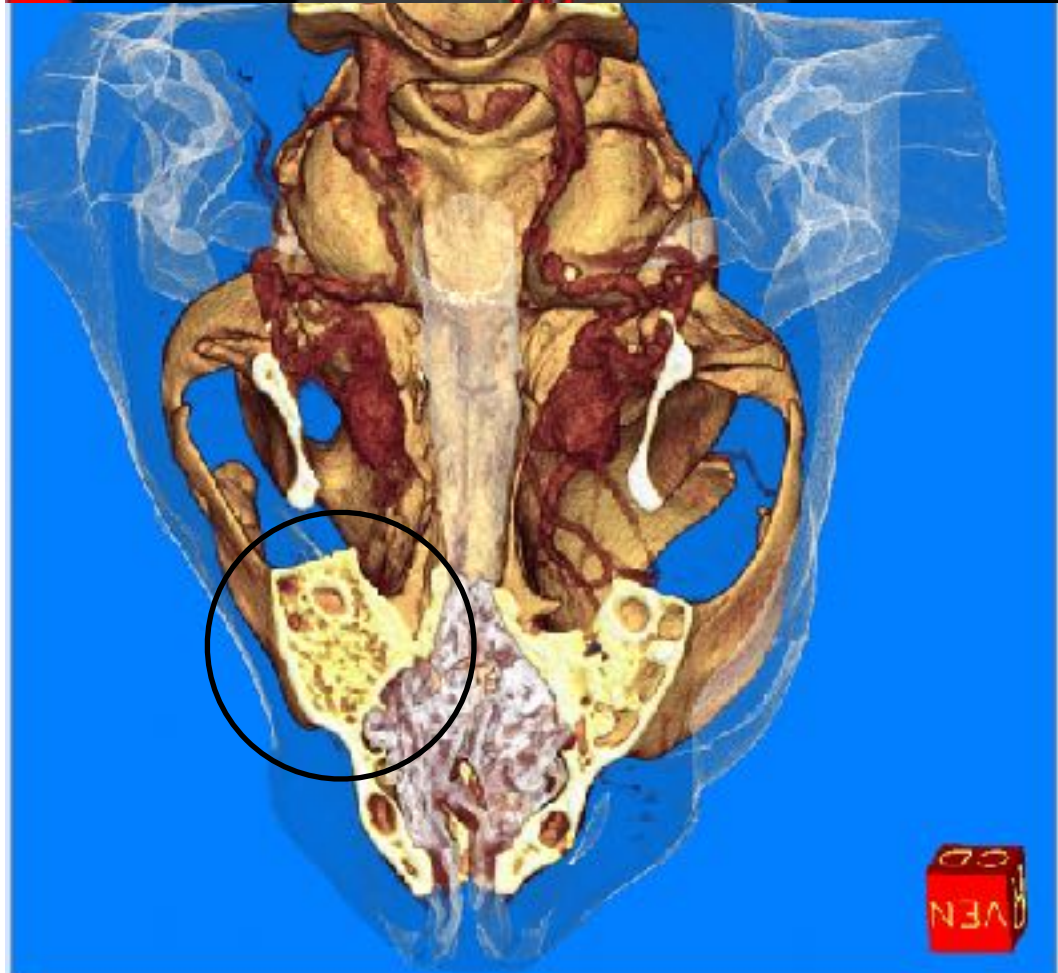
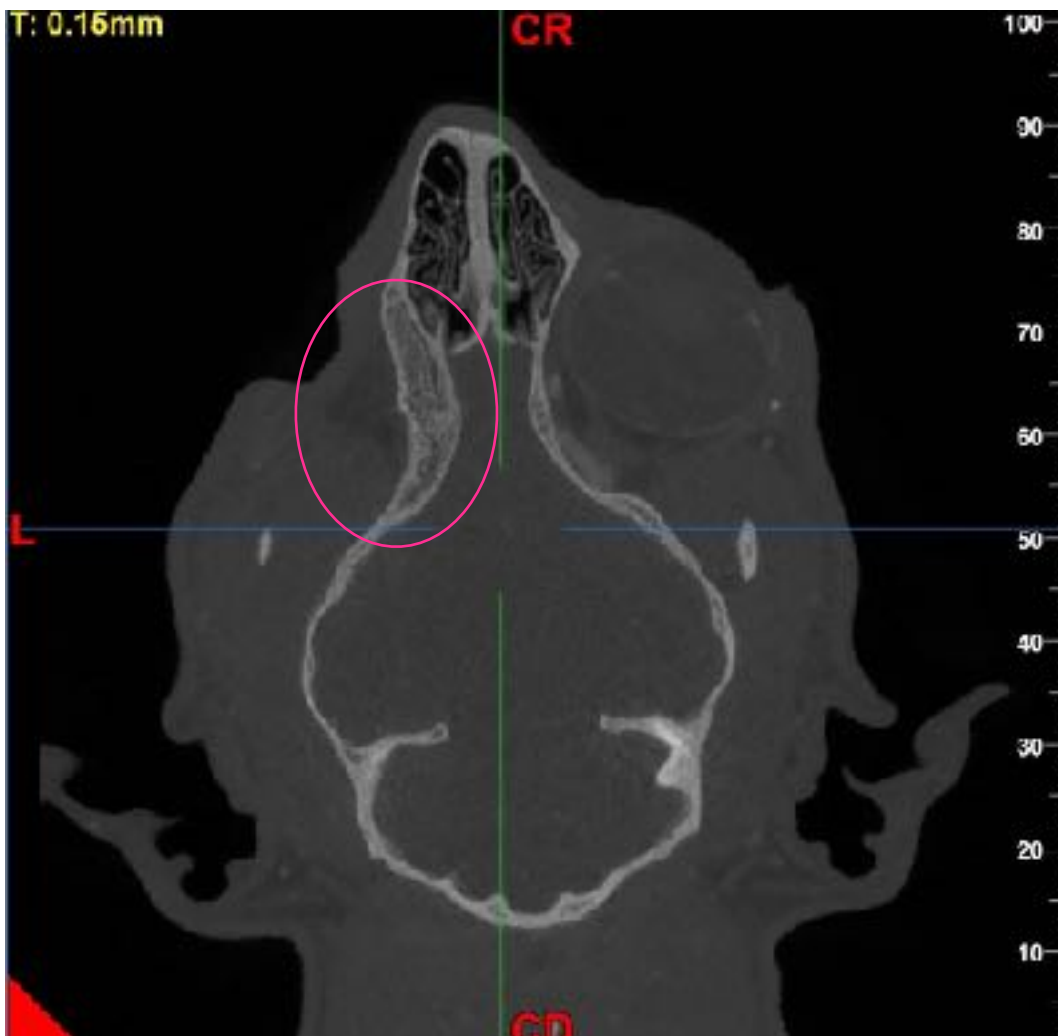
Kot 4 lata female spayed nasal discharge

**3D reconstruction:  
assymetry - left zygomatic  
arch thickened and lifted**



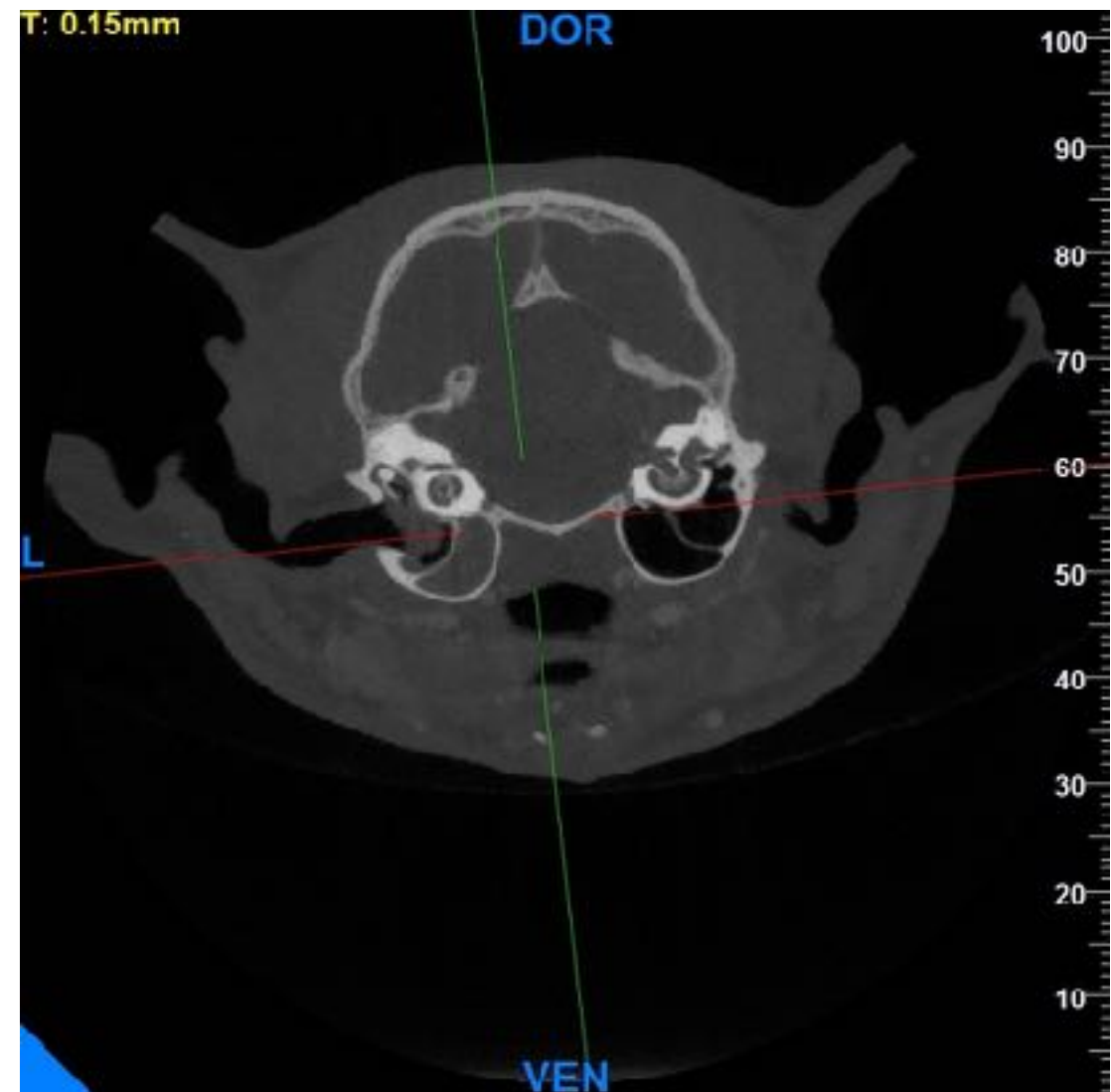
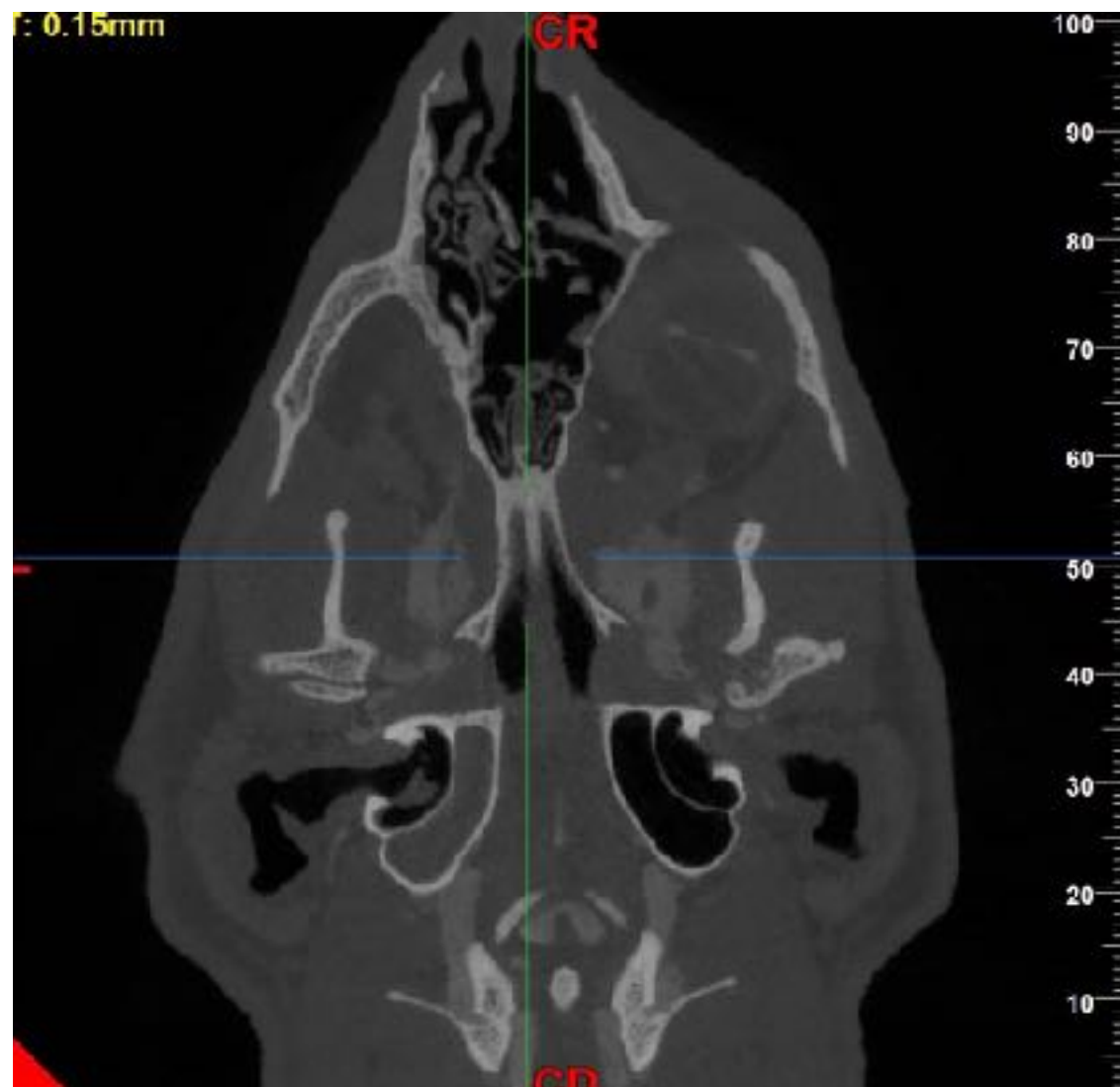


# Findings

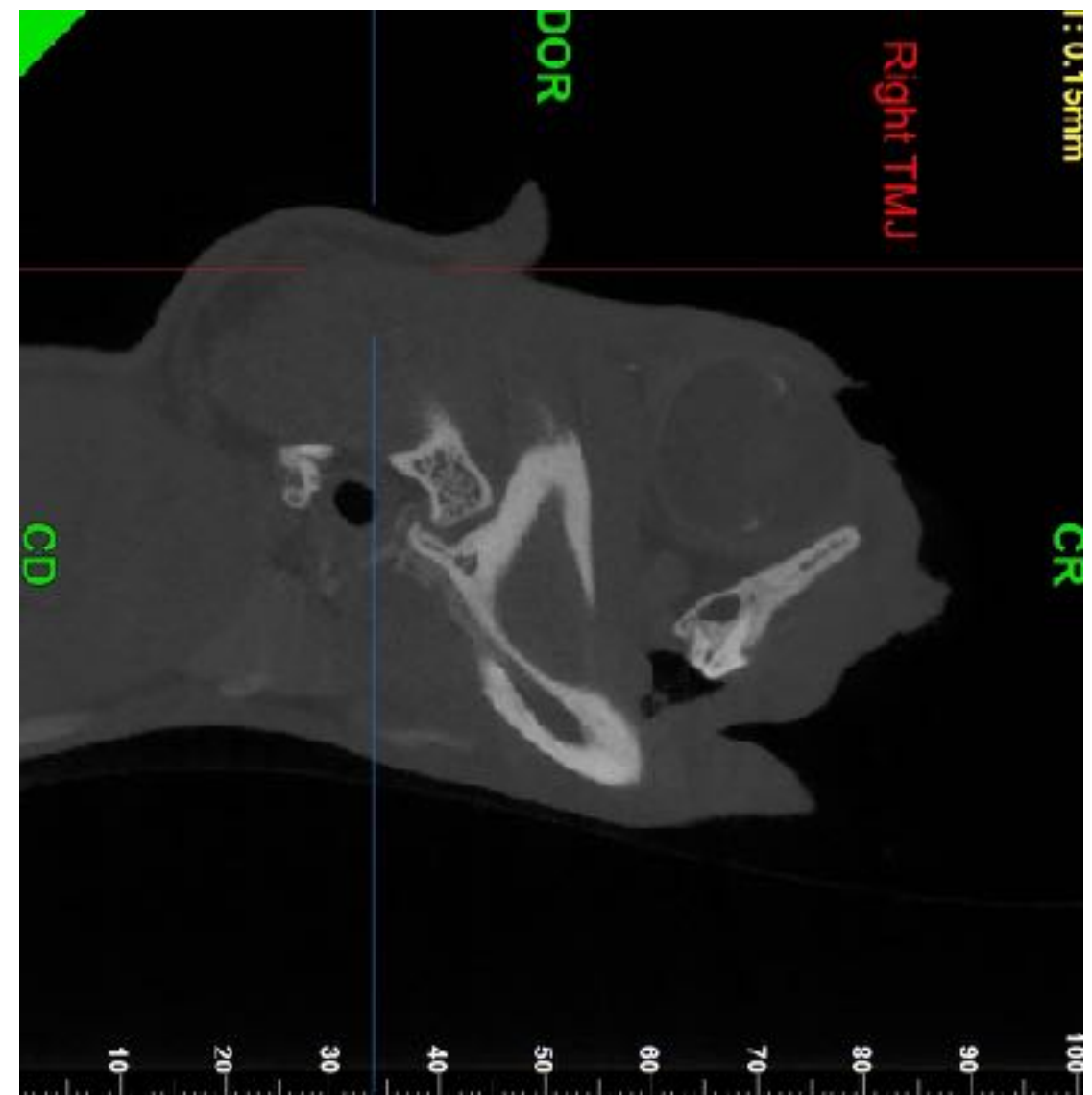
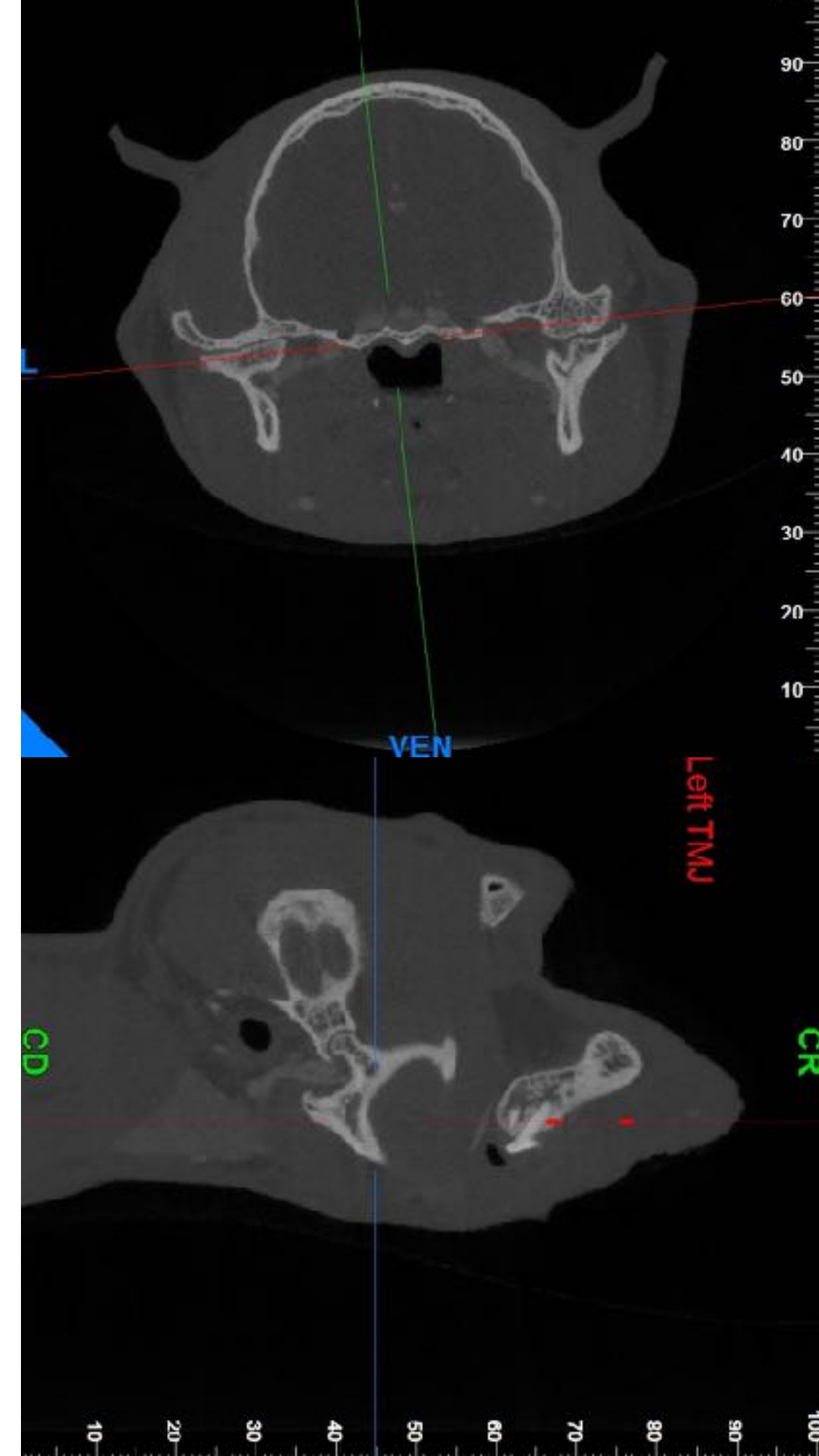


**abnormal tissue in left  
maxilla, my tentative  
suspicion: osteomyelitis**

**Findings: left bulla with liquid, likely damaged tympanic membrane; destroyed nasal structures (turbinates): possible source of sequester.**

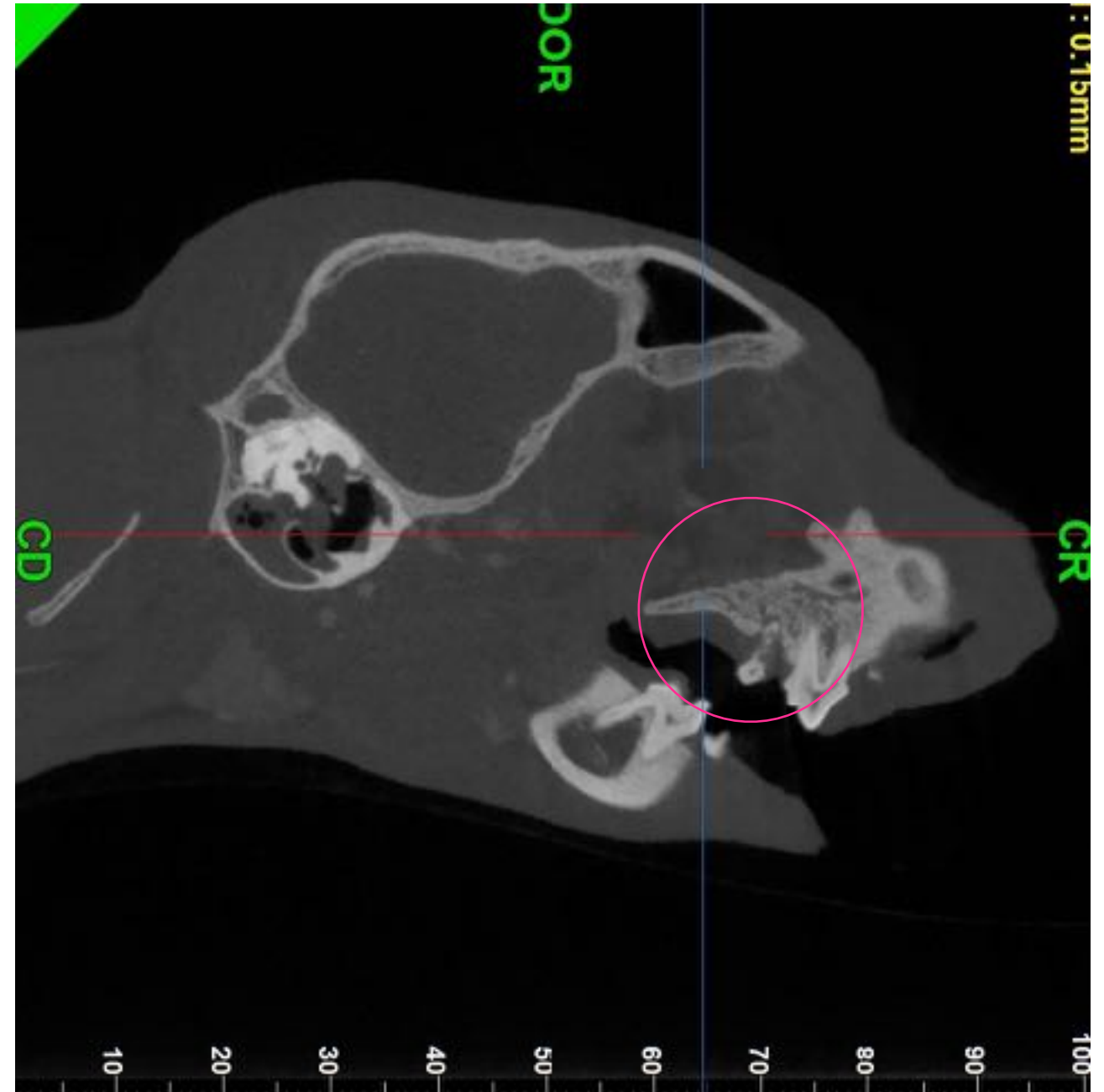
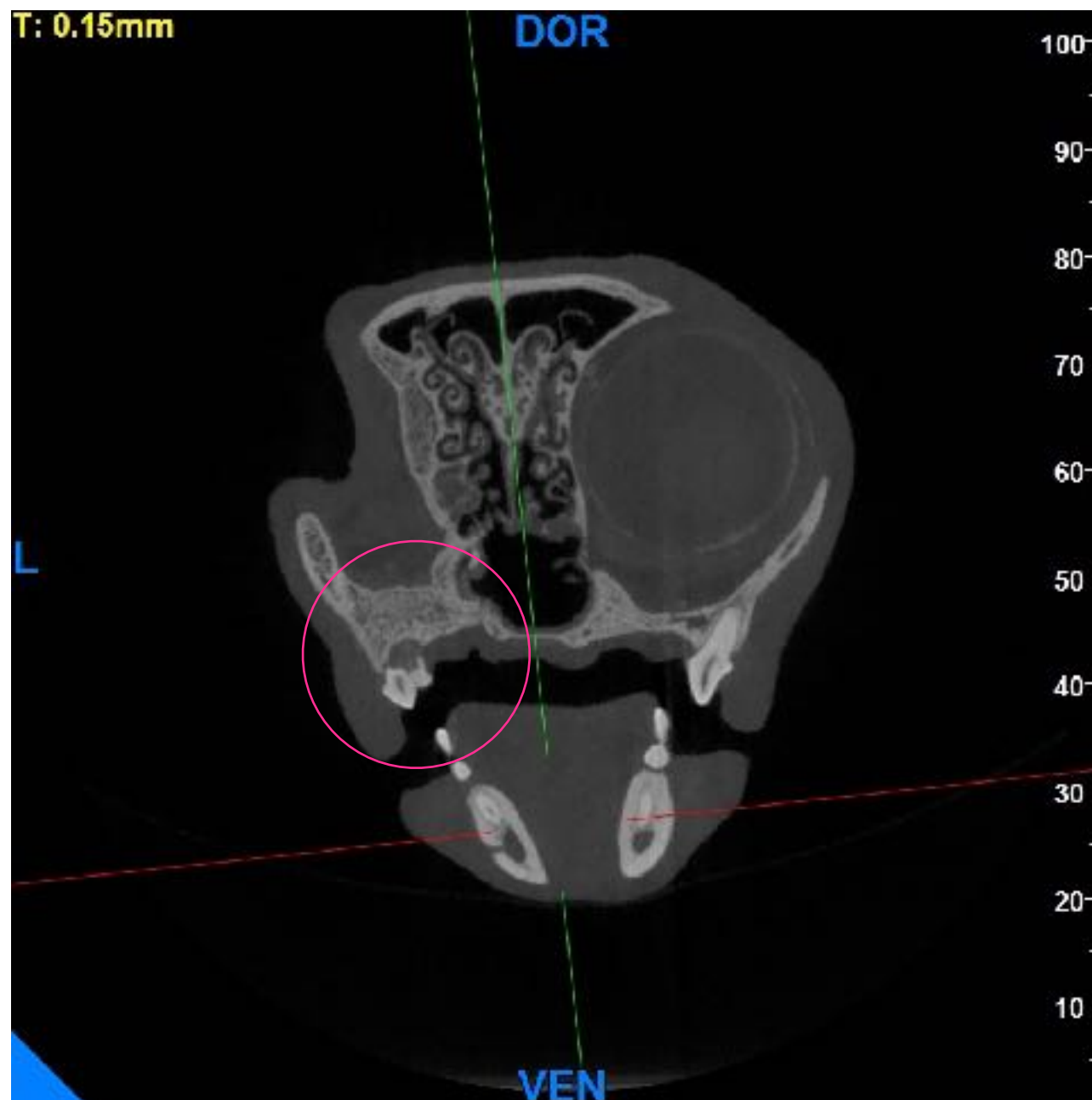


**Findings: right TMJ  
damaged and  
malfunctioned**





**Recomendation: XSS of 208 and biopsy the bone above to 208.**



# Treatment options

- Osteomyelitis - 6-12 weeks of antibiotic treatment
- Malignancy: depending on exact type of tumor.